Multifocal early gastric adenocarcinomas with gastric lipomatosis: An unusual coexistence

Editor,

Gastric cancer has become increasingly common worldwide, responsible for approximately 934,000 new diagnoses and 700,349 deaths, annually.[1] Due to recent advances in endoscopy and radiology, the incidence of multifocal primary cancers seems to be increased. Patients with multifocal gastric cancer accounted for 6-14% of all gastric tumors.[2] Early gastric adenocarcinoma is described as a lesion that is delimited only to the mucosa or submucosa without risk of regional lymph node metastases.[2] Lipomatosis of the stomach can be defined as the submucosal infiltration or accumulation of adipose tissue in the gastric wall, usually resulting in nonspecific gastrointestinal symptoms.[3] Some authors defined gastrointestinal lipomatosis as multiple gastrointestinal lipomas.[4] However, conventional gastrointestinal lipomas are composed of adipose tissue surrounded by a fibrous capsule, which is not observed in gastrointestinal lipomatosis. Herein, we report the synchronous coexistence of a multifocal early gastric adenocarcinoma with gastric lipomatosis in a female patient. To the best of our

knowledge, no case of synchronous multifocal early gastric adenocarcinoma and gastric lipomatosis has been previously reported in the literature.

A 56-year-old female patient was admitted to the Gastroenterology Department of our hospital with a 1-month history of upper abdominal pain and weight loss. Her family history was remarkable in that her father had died of gastric cancer. Her hematological and biochemical variables were within normal limits. Gastric endoscopy revealed severe atrophic gastritis and an ulcerative lesion in the gastric antrum. Pathological diagnosis of the biopsy specimens was gastric adenocarcinoma, intestinal metaplasia, and chronic atrophic gastritis without *Helicobacter pylori*. She underwent subtotal gastrectomy and regional lymph node dissection, and two distinct lesions were identified in the resected specimen [Figure 1]. The first lesion, located in the anterior wall of the antrum, was diagnosed as well-differentiated adenocarcinoma. The tumor, 25 mm × 25 mm in size, invaded the submucosa.

Figure 1: Gross pathology findings of the surgical specimen. (a) Two tan-yellow tumor masses with ulceration were present in the stomach. (b) Cross section through the gastric wall showing the adipose tissue mainly in the submucosa. T:Tumor, M:Mucosa, LP: Lipomatosis, TM: Tunica muscularis

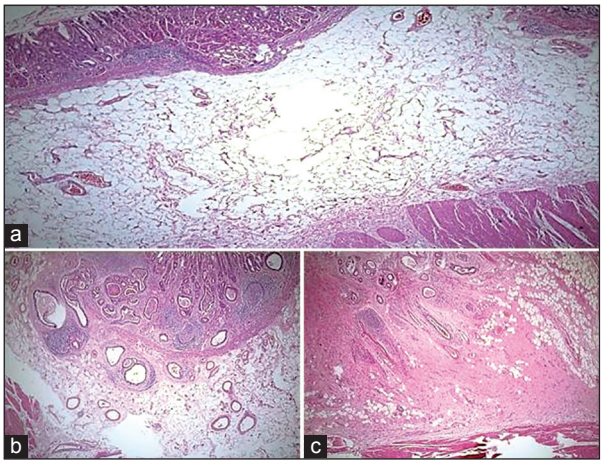

Figure 2: (a) Histologic features of the gastric lipomatosis. Lower magnification showing diffuse fatty infiltration of the submucosa. (b and c) Both of the two tumoral lesions are located predominantly in the submucosa with lipomatosis. (H and E, orginal magnification ×50)

The second lesion, which was also diagnosed as well differentiated adenocarcinoma, was located at the distal side of the first tumor. Its size was 17 mm × 15 mm, and it also invaded the submucosa. Interestingly, sections of the tumor showed diffuse infiltration of the submucosal layer by adipose tissue, separating the muscularis mucosa from the tunica muscularis [Figure 2]. There was no invasion of lymphatic or blood vessels and metastatic neoplasia in the lymph nodes (0/20). The final pathological diagnosis was multifocal early gastric adenocarcinoma with gastric lipomatosis.

Gastric lipomatosis is characterized by gastric infiltration on submucosal layer by adipose tissue and some authors proposed that the term "lipomatosis or lipohyperplasia" should replace the term "lipoma". [3,4] Gastric lipomatosis is a very infrequent condition, and only 11 cases have been described in the literature so far.[4] Although different etiopathogenetic theories, including familial predisposition, chronic irritation, lipid storage diseases, and hamartomatous syndromes, have been proposed, the etiology of gastric lipomatosis remains unknown.[4,5] The simultaneous occurrence of lipomatosis and early gastric adenocarcinoma raises the question whether or not such an occurrence is a simple incidental association or early gastric adenocarcinoma has a causal relationship with lipomatosis.

Nesrin Ugras, Selva Kabul, Ömer Yerci, Ersin Öztürk[1]

Departments Surgical Pathology and [1]General Surgery, Medical Faculty, Uludag University, Bursa, Turkey

Address for correspondence:
Dr. Nesrin Ugras, Department of Pathology, Uludag University School of Medicine, Gorukle, Bursa 16059, Turkey.
E-mail: nesrin_ugras@yahoo.com

REFERENCES

1. Parkin DM, Bray F, Ferlay J, Pisani P. Global cancer statistics, 2002. CA Cancer J Clin 2005;55:74-108.
2. Bearzi I, Ranaldi R. Multifocal early gastric cancer: Morphology and histogenesis. Pathol Res Pract 1986;181:144-7.
3. Ferrozzi F, Tognini G, Bova D, Pavone P. Lipomatous tumors of the stomach: CT findings and differential diagnosis. J Comput Assist Tomogr 2000;24:854-8.
4. Jeong IH, Maeng YH. Gastric lipomatosis. J Gastric Cancer 2010;10:254-8.
5. Devlies F, Hoe LV, Leemans A, Ponette E, Paepe ID. Gastroduodenal lipomatosis. Eur Radiol 1997;7:338-40.

Access this article online	
Quick Response Code:	Website: www.ijpmonline.org
	DOI: 10.4103/0377-4929.142721