Original Article

NRJ

The Neuroradiology Journal
2022, Vol. 35(5) 612–618

DOI: 10.1177/19714009221083143
journals.sagepub.com/home/neu
SAGE

The effectiveness of enterprise stent use on the treatment of intracranial atherosclerosis disease

Oguz Ari[1], Omer F Nas[2], Mehmet F Inecikli[2] and Bahattin Hakyemez[2]

Abstract

Objective: To examine the clinical outcome of Enterprise stent in patients with severe and symptomatic intracranial atherosclerosis.

Material and method: Twenty-five patients who underwent Enterprise stenting between January 2012 and March 2019 were included in this study. Exclusion criteria were previous intracranial stenting and inadequate follow-up. Technical success rates of the procedures were recorded. Clinical outcome was evaluated with pre- and post-treatment modified Rankin Scale scores. The patients were monitored for 18 months clinically and for 14.3 months radiologically.

Results: The mean age of the 15 males and 10 females was 61.6 ± 8.19. Of these 25 patients, 6 (24%) were in the anterior system and 19 (76%) were in posterior system. The mean degree of pre-treatment stenosis was 86.4% ± 7 with the mean lesion length of 12.5 ± 7.5 mm. The residual stenosis rate was 23.8% ± 8.81. Technical success rate was 100%. There were two major complications within the first 30 days (8%). Late major complications (after 30 days) occurred in one case (4%). Stent restenosis was detected in two patients (8%). No intracranial bleeding or mortality was observed.

Conclusion: In this single-center study, we achieved high technical success and tolerable complication rates. Enterprise stent may be a good treatment alternative for severe intracranial stenosis especially in patients resistant to medical treatment when correct patient selection is made. However, further randomized controlled studies, including more cases should be carried out.

Keywords

intracranial atherosclerosis, enterprise stent, endovascular treatment

Introduction

Intracranial atherosclerotic disease (IAD) is one of the most important causes of ischemic stroke and is often associated with recurrent transient ischemic attacks.[1,2]

The main treatment options in IAD are conservative approach, endovascular treatment, and surgery. Conservative strategies consist of medical treatment, lifestyle modification, and thus, optimization of comorbid risk factors. Percutaneous transluminal angioplasty and stenting (PTAS) is one minimally invasive technique that restores blood flow in affected territories. The initial treatment is controversial, especially in symptomatic and severe IAD patients (≥70% narrowing in the vessel lumen). Medical treatment alone or medical and endovascular treatment combination can be preferred.[3]

Endovascular approach in the treatment of IAD was popular at the beginning of the 2000s due to low complication rates.[4] Stenting vs. Aggressive Medical Management for Preventing Recurrent Stroke in Intracranial Stenosis (SAMMPRIS) study showed that the early and late complication rates in the medical treatment group were lower than those of the endovascular treatment group. This study used a self-expandable Wingspan stent (Boston Scientific, Natick, MA, USA) that was approved by Food and Drug Administration (FDA) for medical treatment-resistant severe IAD cases.[5] Some researchers suggested these results may be due to high radial strength of Wingspan stent, which can be associated with the high intra-stent restenosis rates in the follow-up period.[6]

The latest studies showed that some newly developed stents might be effective on the treatment in tortuous vascular structures and long segment complex stenotic plaques since these stents have a flexible design and low intraluminal opening pressure. One of these stents is the Enterprise stent. Enterprise stent (Codman Corporation, Miami Lakes, FL, USA) is self-expandable and was originally designed for wide-necked aneurysm treatment.[7]

The data on Enterprise stent use on IAD treatment in the literature is limited. With this study, we aim to share our experiences about the patients whom we treated using Enterprise stent.

Material and method

Patient selection

This retrospective study included 25 patients who were treated with Enterprise stent between January 2012 and March 2019. The local ethical committee's approval was

[1]Department of Radiology, Bursa City Hospital, Turkey
[2]Department of Radiology, School of Medicine, Bursa Uludag University, Turkey

Corresponding author:
Oguz Ari, Department of Radiology, Bursa City Hospital, Dogankoy, Nilüfer 16059, Bursa, Turkey.
Email: dr.ous.ari@gmail.com

obtained. The IAD diagnosis was verified with Digital subtraction angiography (DSA). The inclusion criteria were patients who experienced recurrent transient ischemic attack (TIA) or ischemic stroke in the distal segment of the intracranial artery despite receiving antiplatelet medical treatment, who were treated with Enterprise stent and who had ≥70% narrowing in the DSA examination before the treatment. Patients under 18 years of age, with non-atherosclerotic stenosis, those with severe neurological disability due to stroke or dementia and treated within 2 weeks after acute cerebral infarction were not included in the study.

Study design

The location, length, character, and degree of stenosis of the atherosclerotic lesion were determined in the diagnostic images made with biplane DSA device (AXIOM Artis, Siemens, Erlangen, Germany) in our department. Warfarin–Aspirin Symptomatic Disease (WASID) method was used to determine the degree of stenosis.[8] Cranial imaging of the patients was performed in our hospital in pre- and post-operation follow-up periods.

Modified Rankin Scale was used to evaluate the neurological state before and after treatment. Technical success criteria in endovascular treatment procedure were determined as full placement of the stent on stenotic segment and less than 50% residual stenosis in the control DSA images after stent placement

Treatment procedure and follow-up

All endovascular treatments were performed by a radiologist who had more than 20 years of experience in neurointerventional radiology. Patients were administered 300 mg acetylsalicylic acid (ASA) and 75 mg clopidogrel for at least 3 days before treatment. The clopidogrel response test was not routinely performed. All procedures were performed under general anesthesia. 6 French (F) diameter vascular access sheath (introducer) was placed in the right femoral artery. After placement of the guiding catheter, a rotational angiography, and 3D reconstruction images were obtained to better measure the parent artery diameter and length of the stenosis. Under a road map, the vessel distal to the stenosis was reached with a micro-guide wire Terumo (Terumo Medical Corporation)]. Then, the stenosis region was reached with Gateway (Stryker, Fremont, California, USA) balloon system over the guidewire. The size of the Gateway balloon was selected as 80% of the diameter of the vessel that was proximal to the stenosis. Angioplasty procedure was performed for 30–60 s with an average pressure of 6–10 atm in the stenosis region with the submaximal angioplasty technique. After the balloon catheter withdrawal, the 0.021-inch delivery microcatheter [Prowler Select Plus (Codman, MA, USA)] was advanced over an exchange microwire and Enterprise stent placement procedure were performed to cover the stenotic lesion completely. After PTAS, a post-stenting angiogram was obtained immediately and 30 min later to ensure no in-stent thrombosis. Balloon angioplasty procedure was repeated on the lesions with insufficient stent gap (<50%) based on the control DSA images obtained right after stent placement procedure in the same session, and sufficient lumen opening was provided.

Medical treatment arrangements were made for the patients as 300 mg ASA and 75 mg clopidogrel a day for first 6–12 weeks after their discharge and then, as daily 300 mg ASA, and also for their accompanying diseases (diabetes, high blood pressure, hyperlipidemia, etc.) Each patient was evaluated in terms of DSA or CT (computed tomography) angiography, intra-stent restenosis, and intimal hyperplasia at 6 months intervals during the follow-up period after the endovascular treatment.

Statistical analysis

Standard deviation, mean, frequency, and other descriptive statistics of the data in the study were obtained with SPSS 23.0 package program (IBM, Armonk, New York, USA).

Results

Patients' characteristics

The study included 25 patients (10 females and 15 males). The mean age was 61.6 ± 8.19. The age range varied between 47 and 79. All the patients were symptomatic, and 60% (15/25) had a history of stroke, while 40% (10/25) had a history of recurrent TIA. No endovascular treatment was performed on patients during the acute period. The mean duration of time between the last ischemic event to stenting was 36.8 ± 17.8 days. The waiting duration between the last symptom and endovascular treatment varied between 15 and 70 days. Table 1 shows general information about the patients.

Lesion features

All 25 patients were examined with preoperative DSA. WASID method was used to determine the degree of stenosis. Reference artery diameters and lesion lengths were determined. Additionally, lesions were divided into three groups according to the LMA (location, morphology, and accessibility) classification based on vascular accessibility.[9] They were classified as Type A, B, and C according to the Mori classification based on morphology.[10] Table 2 shows the lesion features.

Treatment, complications, and follow-up period

Technical success rate in the endovascular treatment was 100%. Residual stenosis rate after stent placement was ≥50% in two lesions. Balloon angioplasty procedure was repeated for these lesions in the same sessions, and targeted luminal opening was ensured. The mean residual stenosis rate was calculated as 23.8% ± 8.81 (10–40%). Emerging infarct, intracranial bleeding, and death were determined as major complications. The major complication rate in the peri-procedural period (during endovascular treatment and the first 30 days after treatment) was 8% (2/25). Newly emerging perforating type pons infarct was observed after the stent placement in the basilar truncus in one of the patients with major complications, while newly emerging infarct areas in the ipsilateral watershed area and permanent decrease in

Table 1. Demographic and clinical characteristics of patients

Variable	Values ([a])
Age	Mean 61.6 ± 8.19 (47–7)
Gender	
Male	*n*:15 (60%)
Female	*n*:10 (40%)
Hypertension	*n*:20 (80%)
Diabetes mellitus	*n*:15 (60%)
Hyperlipidemia	*n*:10 (40%)
CAD	*n*:7 (28%)
PAD	*n*:3 (12%)
Smoking	*n*:14 (56%)
Patterns of infarction	
Hemodynamic	*n*:16 (64%)
Thromboembolic	*n*:4 (16%)
Perforating artery	*n*:5 (20%)
Semptom	
Stroke	*n*:15 (60%)
TIA	*n*:10 (40%)
Time intervals from last event to intervention (day)	Mean 36.8 ± 17.8 (15–7)

TIA: Transient ischemic attack; CAD: Coronary artery disease; PAD: Peripheral artery disease.
[a](n: number, ±: standard deviation).

Table 2. Lesion characteristics

Variable	Values ([a])
Location	
Middle cerebral artery	*n*:3 (12%)
İnternal carotid artery	*n*:3 (12%)
Basilar artery	*n*:10 (40%)
Vertebral artery	*n*:9 (36%)
Stenosis grade	
%70–79	*n*:3 (12%)
%80–89	*n*:7 (28%)
%90–99	*n*:15 (60%)
Mean stenosis degree	%86.4 ± 7 (75–95%)
Reference artery diameter (mm)	Mean 2.51 ± 0.54 (1.6–3)
Lesion length (mm)	Mean 12.5 ± 7.5 (4–2)
Mori classification	
A	*n*:9 (36%)
B	*n*:13 (52%)
C	*n*:3 (12%)
Location, morphology and accessibility classification	
I/II	*n*:22 (88%)
III	*n*:3 (12%)

[a](n: number, ±: standard deviation, mm: millimeter).

muscle strength were observed on the 10th day in the other patient.

The patients were clinically monitored for approximately 18 (6–48) months after endovascular treatment. Imaging follow-ups were performed in 48% (12/25) of the patients with DSA and in 52% (13/25) with CT angiography. Mean angiography (DSA and CT angiography) follow-up duration was 14.3 (6–48) months. The ischemic complication rate in the postprocedural period (30 days later) was 12% (3/25). Non-ischemic complications were not observed. One of the patients (1/25) had a stroke in the third month, and two patients (2/25) had TIA in the sixth and 8 months, respectively. The ischemia findings were in the watershed areas (ipsilateral) of the vascular structures where the stent was placed, and no contralateral ischemia was not detected. No mortality was observed. We defined intra-stent restenosis as >50% narrowing in the lumen. Two patients who showed ischemic complications also had intra-stent restenosis findings (8%). One of these patients was found to have clopidogrel resistance in the subsequent tests, and the lumen opening was provided by performing PTA method and endovascular treatment. Table 3 and 4 show the data on treatment, complications, and follow-up.

Table 3. Patients with post operative intra-stent restenosis.

	Case 1	Case 2
Gender/Age	Female/52	Male/79
Lesion location	ICA	VA
Lesion length (mm)	7.5	11
Mori/LMA classification	B/II	C/II
Pre-stent stenosis/Post- stent residual stenosis (%)	80/20	90/45
Enterprise stent size (mm)	4.5 × 28	4 × 20
Symptom	Permanent decrease in muscle strength	Severe dizziness
Intra-stent restenosis degree	%75	%80
Clopidogrel resistance	+	–

ICA: Internal Carotid Artery; VA: Vertebral Artery; LMA: location, morphology, and accessibility.

Table 4. The data of treatment, complications, and follow-up period.

Variable	Values ([a])
Technical success	*n*:25 (100%)
Residual stenosis (%)	Mean 23.8 ± 8.81 (10–40%)
Periprocedural complication	*n*:5 (20%)
Major	*n*:2 (8%)
Stroke	*n*:2 (8%)
Intracranial bleeding	–
Death	–
Follow-up period with angiography (month)	Mean 14.3 (6–48)
Follow-up period with clinical (month)	Mean 18 (6–48)
Postprocedural complication	*n*:3 (12%)
Stroke	*n*:1 (4%)
TIA	*n*:2 (8%)
Intra-stent restenosis	*n*:2 (8%)

TIA: Transient ischemic attack.
[a](n: number, ±: standard deviation).

A case of severe basilar stenosis who underwent Enterprise stenting is presented in Figure 1 and a case of restenosis at the third month of endovascular treatment is shown in Figure 2.

Discussion

This single-center retrospective study aimed to investigate the feasibility of Enterprise stents for symptomatic IAD patients with severe stenosis. We have compared our results with the relatively limited Enterprise studies in the literature. The study obtained high technical success rate and low periprocedural complication rate.

The therapeutic management of IAD is still controversial. A medical approach that includes effective control of cardiovascular risk factors and lifestyle changes along with antiplatelet drugs is the first recommended treatment method. However, despite aggressive medical treatment, recurrent transient ischemic attacks and ischemic stroke may occur in patients with severe vascular stenosis (70–99%). Endovascular treatment techniques may be more efficient in preventing ischemic strokes for these patients.[10]

Additionally, multicenter randomized controlled SAMMPRIS and VISSIT (Vitesse Intracranial Stent Study for Ischemic Stroke Therapy) studies compared the long-term outcomes of medical treatment and endovascular approach. These studies showed that medical treatment was superior to endovascular treatment in terms of the early and late complications. Thus, endovascular treatment became controversial.[10–12]

In the SAMMPRIS study, the rate of stroke or death within the first 30 days was 14.7% in the endovascular treatment group, and it was 5.8% in the medical treatment group. Although intracranial bleeding was observed in 10 patients, five of whom experienced it in the first 30 days, no intracranial bleeding was observed in the medical treatment group. Considering the long-term results of the study, medical treatment was superior to the endovascular treatment.[12]

On the other hand, SAMMPRIS study was criticized in some ways. The first criticism is that 35% of the patients included in the study were not resistant to medical treatment. Samaniego et al. achieved a considerably low rate of death and stroke within the first 30 days (6.6%) with an endovascular approach. Since 95% of their study cohort were resistant to medical treatment, Samaniego et al. suggested that stenting is a better option for such patients.[13] Second, the mean duration of time between the last ischemic event and stenting was 7 days in the endovascular treatment group. Therefore, most of the patients were treated during the acute or subacute period. Early stenting of unstable atheroma plaque may cause perforator vessel occlusions with the effect of TIA or plaque shift. The results of SAMMPRIS study showed that the majority of periprocedural strokes were due to perforator occlusions. Additionally, early recanalization is associated with reperfusion bleedings due to vulnerable brain parenchyma.[14,15] Another criticism is that the patients were only grouped as TIA or ischemic stroke in SAMMPRIS. However, IAD may cause an artery-to-artery embolism, local perforating ischemia, hemodynamic hypoperfusion, or a combination of these, and ischemic stroke.[16] The WEAVE trial (Wingspan Stent System Post-Market Surveillance) is a post-market surveillance trial mandated by the FDA to assess the periprocedural safety of the Wingspan Stent system in the treatment of symptomatic IAD. According to this trial, periprocedural complication rate was found 2.6% and they emphasize that proper patient selection following the on-label usage guidelines.[17]

The patients who had a stroke due to hemodynamic hypoperfusion with weak collateral vascularity may benefit more from endovascular treatment.[18] Huang et al. treated 70 lesions in 67 patients with Enterprise stents, and their study

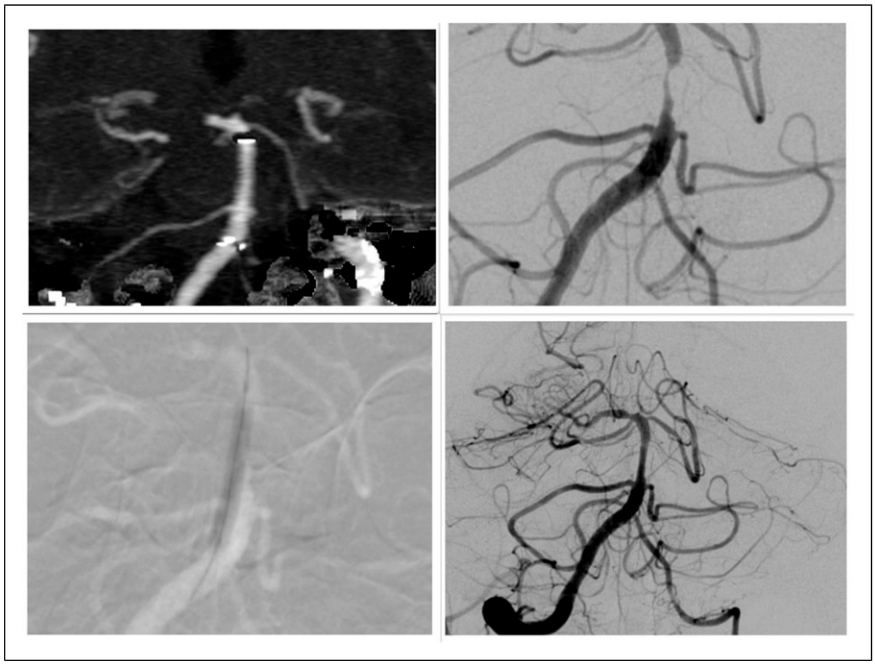

Figure 1. Enterprise stent placement in basilar artery stenosis; (a) Severe stenosis in basilar truncus; DSA image, (b) Endovascular treatment; angioplasty procedure before stent, (c) Control DSA examination in the third month; normal intra-stent lumen flow, (d) Control computed tomography angiography examination in the 12th month; normal stent placement and intraluminal filling. DSA: Digital subtraction angiography.

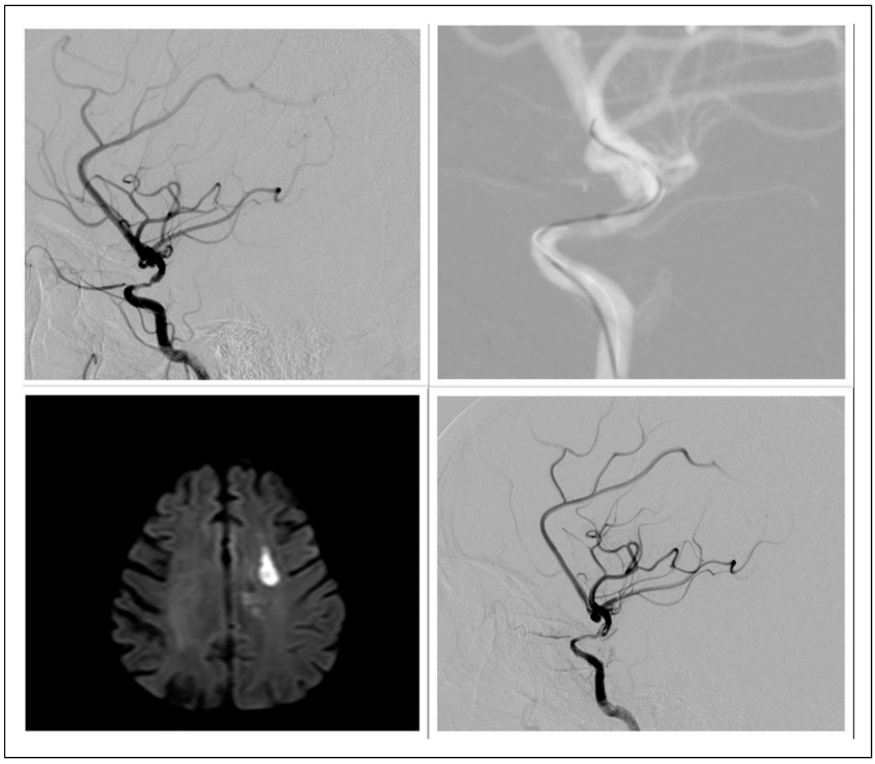

Figure 2. Endovascular treatment and third month restenosis complication of a 56-year-old woman who consulted with right hemiparesis and underwent medical treatment; (a) Diagnostic DSA; significant stenosis is observed in Left Internal Carotid Artery supraclinoid segment, (b) Endovascular treatment; first angioplasty and then stent placement were performed on the stenosis segment, (c) Diffusion MR examination on the case who consulted with recurrent right hemiparesis in the third month; newly-emerging infarct areas in left centrum semiovale, (d) Control DSA image; intra-stent restenosis findings. DSA: Digital subtraction angiography.

only included the patients with hypoperfusion related symptoms and excluded patients with emboli- and perforator ischemia-related symptoms. Complication rate within the first 30-day was 4.4% Hung et al.'s study.[19] SAMMPRIS study also found that insufficient operator experience and Wingspan stent which has some difficulties in technical use may also increase the rate of periprocedural complications.[20,21]

Our low periprocedural complication rate (8%) compared to the SAMMPRIS study might be related to the facts that all of the patients were resistant to medical treatment, no stenting

was performed during the acute period, the operator had much experience, and Enterprise stent was used. Additionally, SAMMPRIS study revealed that the recurrent stroke rate at the end of a year in the medical treatment group was 12.2% despite aggressive medical treatment.[12] In our study, we observed that only one patient (4%) had a stroke in the postprocedural period.

One of the critical problems after intracranial stenting is the formation of intra-stent restenosis. Intimal hyperplasia may cause restenosis in stents with high radial strength. It is not known which endovascular technique reduces the incidence of intra-stent restenosis. Furthermore, intra-stent restenosis can be associated with various factors. However, the incidence of intra-stent restenosis changes based on the type of stent used. There are studies showing that the rate of restenosis is low in especially self-expandable stents with low radial strength and drug-eluting stents.[5,20]

The Wingspan One-year Vascular Events and Neurologic Outcomes trial is the natural extension of the WEAVE trial and assessed the 1-year follow-up outcomes in patients stented in the WEAVE trial. The study found 8.5% 1-year stroke and death rate in 129 patients treated on-label Wingspan stent for symptomatic IAD. This 1-year stroke and death rate was 20% in the stenting group of SAMMPRIS. Also they defined restenosis as 70% narrowing or greater and rate was found 17.6%.[21] Some researchers asserted that high radial strength of Wingspan stents increases the early period intra-stent restenosis risk, and thus, it may cause periprocedural complications in complex stenotic lesions due to its rigid structure.[22–24] In our Enterprise study major stroke rate was 4% on 1 year follow-up. Although we defined intra-stent restenosis as 50% narrowing or greater, we found two symptomatic patients (8%) with restenosis. On the other hand, Enterprise stent is a self-expandable stent with nitinol structure and closed-cell design, and is designed for the treatment of the wide-necked aneurysms. In the in-vitro study by Krishek et al., Enterprise stent had a lower radial strength than especially Wingspan stent.[25] Vajda et al. treated 209 intracranial atherosclerotic lesions in 189 patients using Enterprise stent. The technical success rate was 100%, and the neurologic morbidity and mortality rate was 7.7% in the first 30 days, and it was 0.9% after 30 days.[26]

Wang et al. treated 62 lesions in 60 patients using the Enterprise stent. The perioperative complication rate was 8.3%, and no deaths and permanent morbidity were observed. Lesions were monitored for approximately 6 months in Wang et al.'s study. Seventy-two percent of the lesions were checked with DSA in terms of restenosis, and restenosis was observed in six patients (13.3%). Ischemic symptoms were observed in most of the restenosis patients. They revealed that symptomatic intra-stent restenosis is associated with residual stenosis rates and the pre-treatment length of the lesion.[27] The present study found intra-stent restenosis in two patients (8%). Both cases were symptomatic, and one of them had clopidogrel resistance and received endovascular treatment again.

Other studies in the literature using Enterprise stent also revealed that technical success rates were quite high, and periprocedural complication rates and intra-stent restenosis rates were low.[28–30] This might be due to the low radial strength and more flexible structure of the Enterprise stent.

The main limitations of this study are single-center experience, retrospective design, low number of patients, and a follow-up period less than 2 years in the majority of the patients. Finally, we have primarily employed CTA due to its less invasive nature and low DSA imagining rates in the present study compared to the literature might have shown the restenosis and intimal hyperplasia rates also low.

Our study concluded that the short- and mid-term complication rates of the Enterprise stents in the treatment of IAD are low, and technical success rate is high. Similar to the studies in the literature, this study showed that endovascular treatment may be a good alternative, especially in patients resistant to medical treatment when correct patient selection is made. Randomized controlled clinical studies should be conducted to determine the effectiveness and reliability of Enterprise stent use more accurately.

Declaration of conflicting interests

The author(s) declared no potential conflicts of interest with respect to the research, authorship, and/or publication of this article.

Funding

The author(s) received no financial support for the research, authorship, and/or publication of this article.

ORCID iD

Oguz Ari https://orcid.org/0000-0003-4318-3401

References

1. Resch JA, Loewenson RB and Baker AB. Physical factors in the pathogenesis of cerebral atherosclerosis. *Stroke* 1970; 1(2): 77–85.
2. Manzano JJF, De Silva DA, Pascual JLR, et al. Associations of ankle-brachial index (ABI) with cerebral arterial disease and vascular events following ischemic stroke. *Atherosclerosis* 2012; 223(1): 219–222.
3. Cui XP, Lin M, Mu JS, et al. Angioplasty and stenting for patients with symptomatic intracranial atherosclerosis: study protocol of a randomised controlled trial. *BMJ Open* 2016; 6(11): e012175.
4. Leung TW, Simon CH, Lam WW, et al. The NIH registry on use I wingspan stent for symptomatic 70–99% intracranial arterial stenosis. *Neurology* 2008; 71(14): 1124–1125.
5. Ding D, Starke RM, Crowley RW, et al. Role of stenting for intracranial atherosclerosis in the post-SAMMPRIS era. *Biomed Res Int* 2013; 2013: 304320.
6. Vajda Z, Aguilar M, Göhringer T, et al. Treatment of intracranial atherosclerotic disease with a balloon-expandable paclitaxel eluting stent. *Clin Neuroradiol* 2012; 22(3): 227–233.
7. Higashida RT, Halbach VV, Dowd CF, et al. Initial clinical experience with a new self-expanding nitinol stent for the treatment of intracranial cerebral aneurysms: the cordis enterprise stent. *AJNR Am J Neuroradiol* 2005; 26(7): 1751–1756.
8. Samuels OB, Joseph GJ, Lynn MJ, et al. A standardized method for measuring intracranial arterial stenosis. *AJNR Am J Neuroradiol* 2000; 21(4): 643–646.
9. Jiang W-J, Wang Y-J, Du B, et al. Stenting of symptomatic M1 stenosis of middle cerebral artery: an initial experience of 40 patients. *Stroke* 2004; 35(6): 1375–1380.

10. Mori T, Kazita K, Chokyu K, et al. Short-term arteriographic and clinical outcome after cerebral angioplasty and stenting for intracranial vertebrobasilar and carotid atheroscleroticocclusive disease. *AJNR Am J Neuroradiol* 2000; 212: 249–254.
11. Luo J, Wang T, Gao P, et al. Endovascular treatment of intracranial atherosclerotic stenosis: current debates and future prospects. *Front Neurology* 2018; 9: 666.
12. Chimowitz MI, Lynn MJ, Derdeyn CP, et al. Stenting versus aggressive medical therapy for intracranial arterial stenosis. *New Engl J Med* 2011; 365(11): 993–1003.
13. Samaniego EA, Tari-Capone F, Linfante I, et al. Wingspan experience in the treatment of symptomatic intracranial atherosclerotic disease after antithrombotic failure. *J Neurointerv Surg* 2013; 5(4): 302–305.
14. Park S, Kim J-H, Kwak JK, et al. Intracranial stenting for severe symptomatic stenosis: self-expandable versus balloon-expandable stents. *Interv Neuroradiol* 2013; 193: 276–282.
15. Fiorella D, Derdeyn CP, Lynn MJ, et al. Detailed analysis of periprocedural strokes in patients undergoing intracranial stenting in stenting and aggressive medical management for preventing recurrent stroke in intracranial stenosis (SAMMPRIS). *Stroke* 2012; 43(10): 2682–2688.
16. IzumI T, Imamura H, SakaI N, et al. Angioplasty and stenting for intracranial stenosis. *Neurol Med Chir* 2013; 54(1): 46–53.
17. Alexander MJ, Zauner A, Chaloupka JC, et al. WEAVE trial: final results in 152 on-label patients. *Stroke* 2019; 50(4): 889–894.
18. Banerjee C and Chimowitz MI. Stroke caused by atherosclerosis of the major intracranial arteries. *Circ Res* 2017; 120(3): 502–513.
19. Huang C-M, Hong Y-F, Xing S-H, et al. Thirty-day outcomes of the enterprise stent in treating hypoperfusion of symptomatic intracranial stenosis. *World Neurosurg* 2019; 129: e429–e435.
20. Park S, Lee D-G, Chung W-J, et al. Long-term outcomes of drug-eluting stents in symptomatic intracranial stenosis. *Neurointervention* 2013; 8(1): 9–14.
21. Alexander MJ, Zauner A, Gupta R, et al. The WOVEN trial: wingspan one-year vascular events and neurologic outcomes. *J NeuroInterv Surg* 2021; 13(4): 307–310.
22. Zhao L-B, Park S, Lee D, et al. Mechanism of procedural failure related to wingspan. *Neurointervention* 2012; 7(2): 102.
23. Nahab F, Lynn MJ, Kasner SE, et al. Risk factors associated with major cerebrovascular complications after intracranial stenting. *Neurology* 2009; 7223: 2014–2019.
24. Abou-Chebl A and Steinmetz H. Critique of "stenting versus aggressive medical therapy for intracranial arterial stenosis" by Chimowitz et al in the New England journal of medicine. *Stroke* 2012; 432: 616–620.
25. Krischek Ö, Miloslavski E, Fischer S, et al. A comparison of functional and physical properties of self-expanding intracranial stents [neuroform3, wingspan, solitaire, leo (+), enterprise]. *Minim Invasive Neurosurg* 2011; 54(1): 21–28.
26. Vajda Z, Schmid E, Güthe T, et al. The modified Bose method for the endovascular treatment of intracranial atherosclerotic arterial stenoses using the enterprise stent. *Neurosurgery* 2012; 70(1): 91–101.
27. Wang X, Wang Z, Wang C, et al. Application of the enterprise stent in atherosclerotic intracranial arterial stenosis: a series of 60 cases. *Turk Neurosurg* 2016; 26(1): 69–76.
28. Salik AE, Selcuk HH, Zalov H, et al. Medium-term results of undersized angioplasty and stenting for symptomatic high-grade intracranial atherosclerotic stenosis with Enterprise. *Interv Neuroradiol* 2019; 255: 484–490.
29. Lee K-Y, Chen DY-T, Hsu H-L, et al. Undersized angioplasty and stenting of symptomatic intracranial tight stenosis with Enterprise: evaluation of clinical and vascular outcome. *Interv Neuroradiol* 2016; 222: 187–195.
30. Feng Z, Duan G, Zhang P, et al. Enterprise stent for the treatment of symptomatic intracranial atherosclerotic stenosis: an initial experience of 44 patients. *BMC Neurol* 2015; 151: 187.